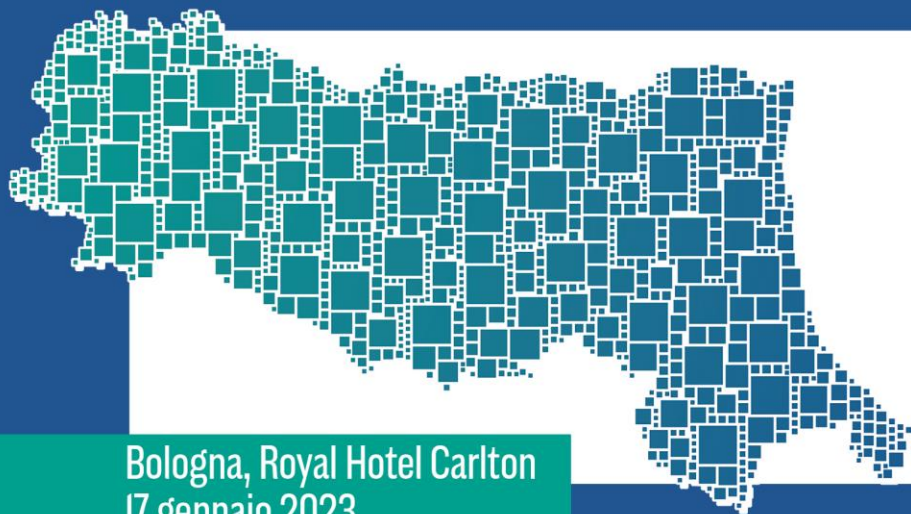


Il management del linfoma primitivo cutaneo di derivazione T-lymfocitaria nell'ambito della regione Emilia-Romagna



Gestione del Linfoma T primitivo cutaneo

Andrea Conti, Dermatologia

Melania Celli, Ematologia

Bologna, Royal Hotel Carlton
17 gennaio 2023

Ospedale Infermi di Rimini, AUSL Romagna

Disclosures of Name Surname

Andrea Conti:

Schering-Plough, Wyeth, Abbvie, MDS, Pfizer, Janssen Cilag, Novartis, Eli Lilly, UCB, Leo Pharma, Biogen, Sandoz, Almirall, Boehringer Ingelheim, Pfizer.

Melania Celli:

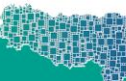No conflict of interest



Il management del linfoma primitivo cutaneo di derivazione T-linfocitaria nell'ambito della regione Emilia-Romagna



Bologna, Royal Hotel Carlton - 17 gennaio 2023



Presse Med 51 (2022) 104126



Available online at
ScienceDirect
www.sciencedirect.com

Elsevier Masson France
EM|consulte
www.em-consulte.com



Quarterly Medical Review
Cutaneous Lymphomas

Primary cutaneous lymphoma: the 2018 update of the WHO-EORTC classification

Rein Willemze*

Department of Dermatology, Leiden University Medical Center, Leiden, The Netherlands



CME Article

The 2018 update of the WHO-EORTC classification for primary cutaneous lymphomas

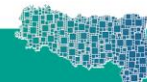Rein Willemze,¹ Lorenzo Cerroni,² Werner Kempf,³ Emilio Berti,⁴ Fabio Facchetti,⁵ Steven H. Swerdlow,⁶ and Elaine S. Jaffe⁷

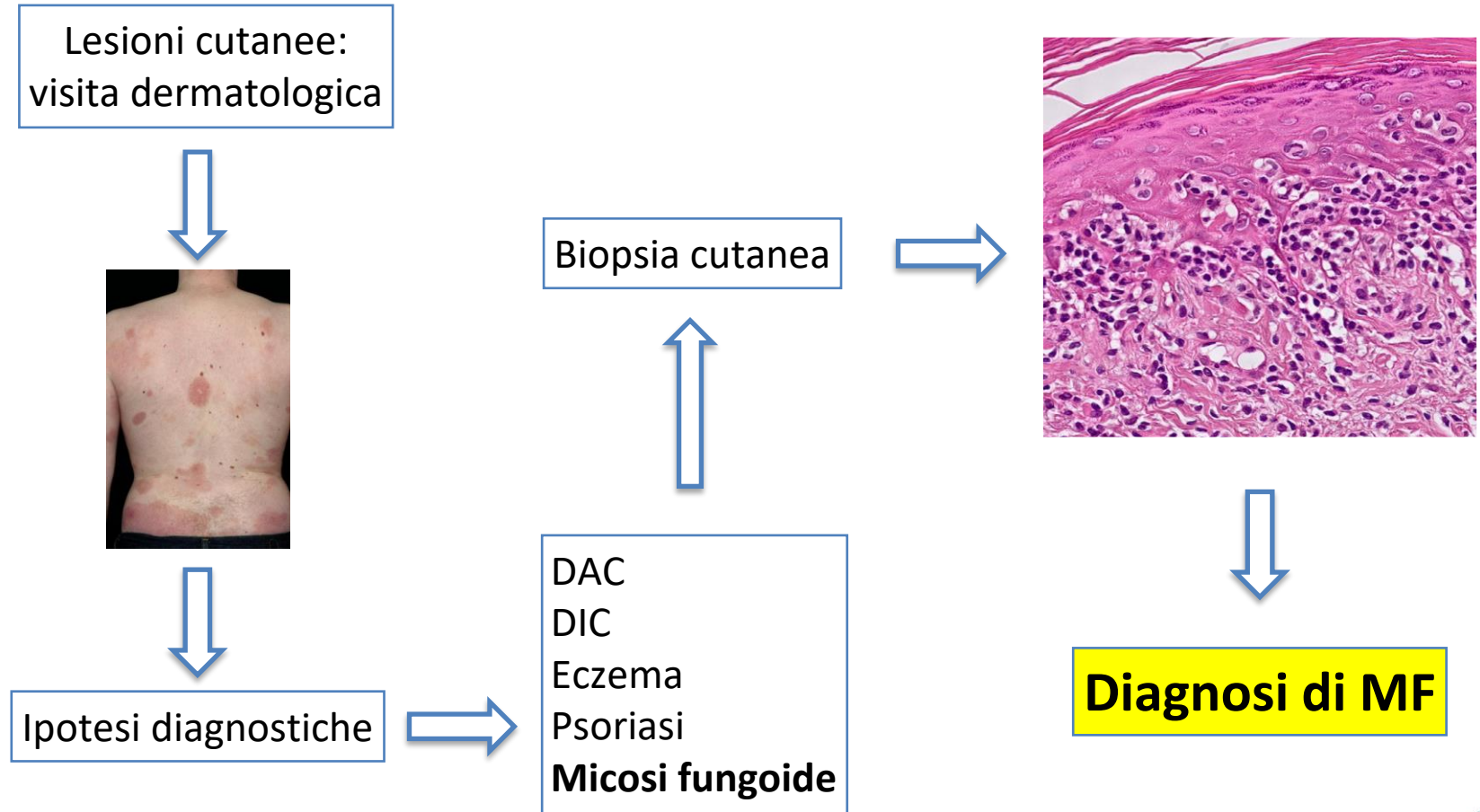
Relative frequency and prognosis of primary cutaneous lymphomas included in the 2018 update of the WHO-EORTC classification [5].

WHO-EORTC Classification 2018	Frequency (%)#	5-year DSS (%) [*]
Cutaneous T-cell lymphomas		
Mycosis fungoides	39	88
Mycosis fungoides variants		
• Folliculotropic MF	5	75
• Pagetoid reticulosis	<1	100
• Granulomatous slack skin	<1	100
Sézary syndrome	2	36
Adult T-cell leukemia/lymphoma	<1	NDA
Primary cutaneous CD30-positive lymphoproliferative disorders		
• Primary cutaneous anaplastic large cell lymphoma	8	95
• Lymphomatoid papulosis	12	99
Subcutaneous panniculitis-like T-cell lymphoma	1	87
Extranodal NK/T-cell lymphoma, nasal type	<1	16
Chronic active EBV infection	<1	NDA
Primary cutaneous peripheral T-cell lymphoma, rare subtypes		
• Primary cutaneous γ/δ T-cell lymphoma	<1	11
• Primary cutaneous aggressive epidermotropic CD8-positive T-cell lymphoma (provisional)	<1	31
• Primary cutaneous CD4+ small/medium T-cell LPD (provisional)	6	100
• Primary cutaneous acral CD8+ T-cell lymphoma (provisional)	<1	100
Primary cutaneous peripheral T-cell lymphoma, NOS	2	15
Cutaneous B-cell lymphomas		
Primary cutaneous marginal zone lymphoma	9	99
Primary cutaneous follicle center lymphoma	12	95
Primary cutaneous diffuse large B-cell lymphoma, leg type	4	56
EBV-positive mucocutaneous ulcer (provisional)	<1	100
Intravascular large B-cell lymphoma	<1	72

DSS: disease-specific survival; NDA: no data available; LPD: lymphoproliferative disorder; NOS: not otherwise specified.

^{*} Based on data included in Dutch and Austrian cutaneous lymphoma registries between 2002 and 2017.





Gestione della MF

Stadiazione



- Esami ematochimici
- Tipizzazione linfocitaria e indagini molecolari, se indicato
- Esami radiologici (TC-PET)
- Visita ematologica



MF localizzata



**MF avanzata/
SS**

Terapia:

- SDT
- UV
- MTX
- RT

Follow up
(dermo + emato)



Perdita di efficacia tp
Evoluzione malattia

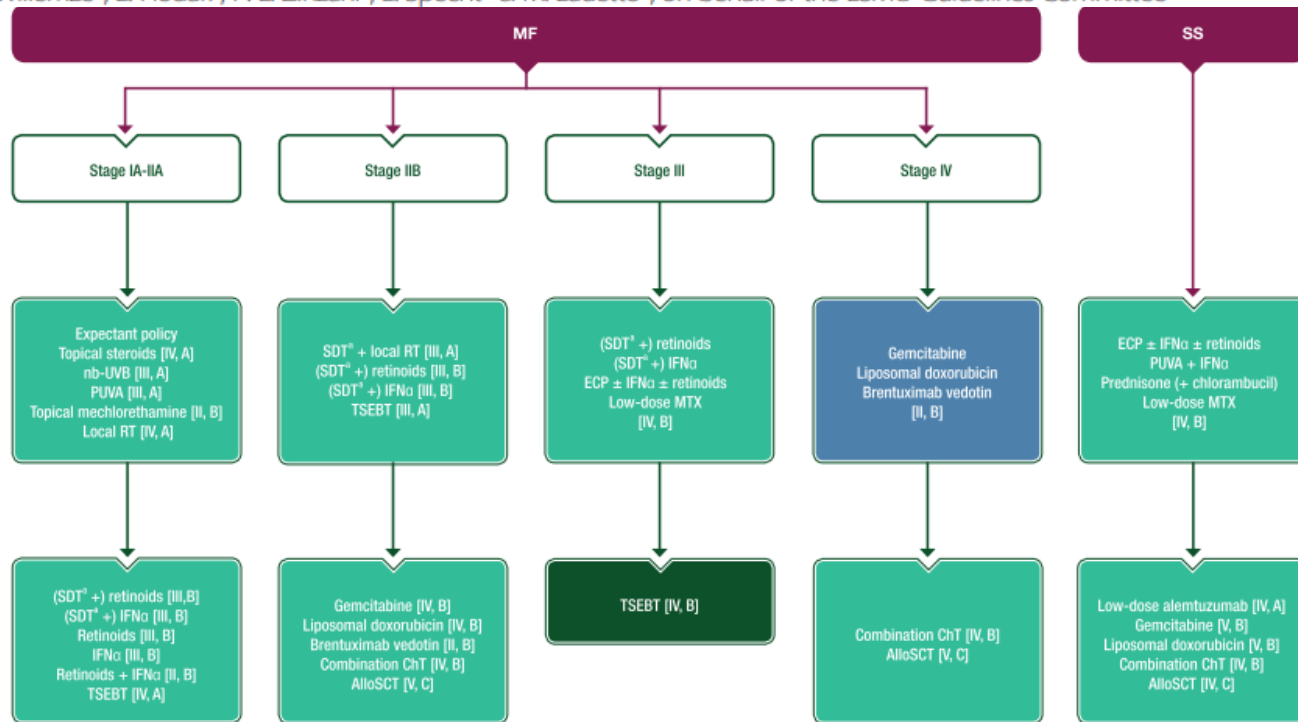


Gestione ematologica
+
FU dermatologico

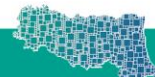

Primary cutaneous lymphomas: ESMO Clinical Practice Guidelines for diagnosis, treatment and follow-up[†]

R. Willemze¹, E. Hodak², P. L. Zinzani³, L. Specht⁴ & M. Ladetto⁵, on behalf of the ESMO Guidelines Committee*



AlloSCT, allogeneic stem cell transplantation;
ChT, chemotherapy;
ECP, extracorporeal photopheresis;
RT, radiotherapy;
SDT, skin-directed therapy;
TSEBT, total skin electron beam therapy.





National
Comprehensive
Cancer
Network®

NCCN Guidelines Version 1.2023 **Mycosis Fungoides/Sezary Syndrome**

Stadio IB-IV

Tp sistemica + SDT

- Bexarotene
- IFN alfa
- MTX
- Mogamulizumab
- BV

Tp combinata (ECP + INF alfa +/- retinoidi)

Mono/polichemioterapia (gemcitabina, doxo liposomiale, CHOP)

(vorinostat, palatrexate, alemtuzumab, romidepsina, pembrolizumab)

